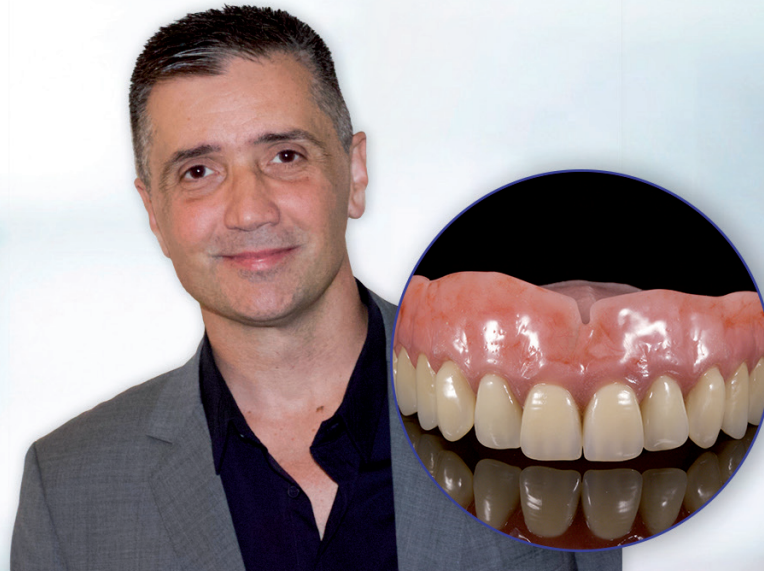



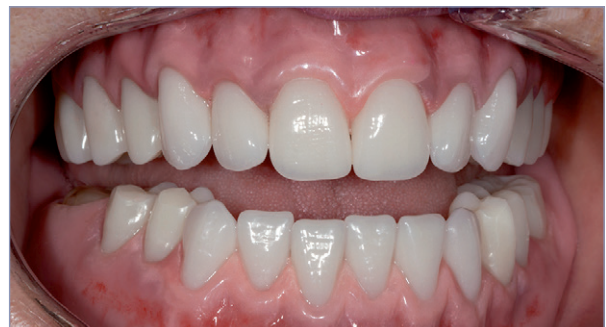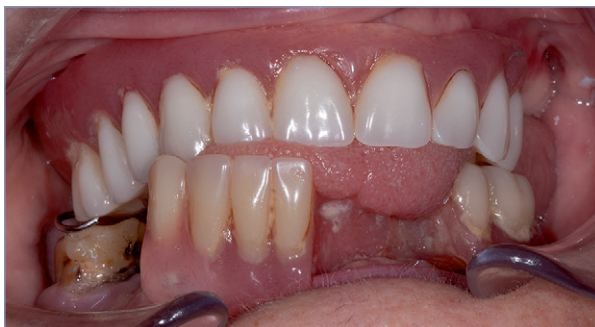VITAPAN EXCELL®: Efficiency and brilliance based on esthetic guidelines.

Denturist Daniel Lavrin, London, UK

When a smile is revitalized using ceramic restorations, esthetic guidelines are followed and implemented meticulously so that optimal results can be achieved. Smile Design – that's what everybody is talking about when it comes to fixed ceramics. Attention to detail is also an established practice when fabricating restorations. The anatomy of the hard tooth substance is reproduced three-dimensionally during ceramic layering. Dentin and enamel materials form a natural unit. So why should

these standards not apply for full dentures too? After all, denture wearers want an esthetic outcome just like any other patient. These days, younger denture wearers in particular want their dentures to look natural rather than artificial. As a dental technician, if you have the opportunity of completely reworking the red-white esthetics, then you should take advantage of the opportunity.

Initial situation vs. final result



Integrated esthetics

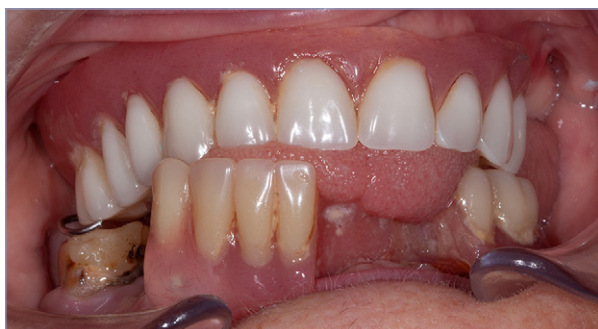After all, the esthetic guidelines that hold true for all disciplines in dental technology should, of course, also apply for full dentures: the tooth axes, contact surfaces, angle characteristics, cervical dimension, gingival margin and length-width ratio should be designed like natural dentition. The basic requirement in this respect is a denture tooth that meets esthetic guidelines and provides an anatomical structure similar to that of natural dentition. And that's the challenge: denture teeth generally – for whatever reason – do not meet esthetic guidelines and have a lifeless and monotonous appearance when it comes to layering. The vestibular morphology is a flat

surface between two ridges without any texture at all, which is why denture teeth of this kind simply cannot offer a natural appearance. The VITAPAN EXCELL (VITA Zahnfabrik, Bad Säckingen, Germany) denture tooth meets esthetic guidelines, is layered three-dimensionally using enamel, dentin and cervical material, and is pressed from a single mold and cured. The morphology and texture of real teeth was consistently implemented when creating the mould. The following case report demonstrates the resulting benefits, not just in terms of esthetics but also for setup.

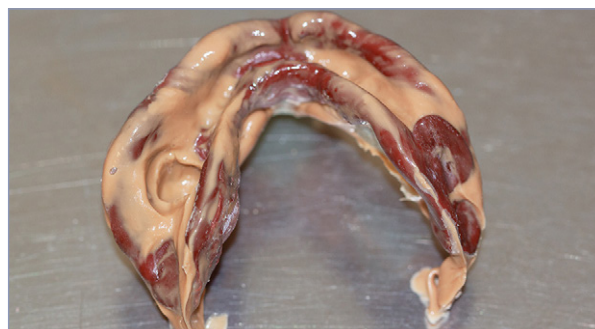Case study

A 58-year-old female patient presented in the dental practice, as she was dissatisfied with both the function and the esthetics of her current restoration. When chewing, the partial denture (lower jaw) and the full denture (upper jaw) would slip back and forth and did not provide a secure grip. The denture teeth appeared lifeless and the mucogingival areas were smooth and level with an artificial appearance. Following extractions in the lower jaw, region 31 to 34 did not have any restoration, as the partial denture had not been extended. Only tooth 46 was still present, which the patient insisted she wanted to keep. The molar proved worth retaining and showed no clinical or radiological signs of severe periodontal damage. Once the impact of a partial denture on the only remaining tooth (46) had been explained to the patient, it was decided that the new lower denture should be designed so that in the event of tooth loss, a denture tooth could be added by making minimal changes to the design of the denture. The decision was therefore taken to work around tooth 46 during fabrication of both dentures. The patient wanted a new restoration with a natural

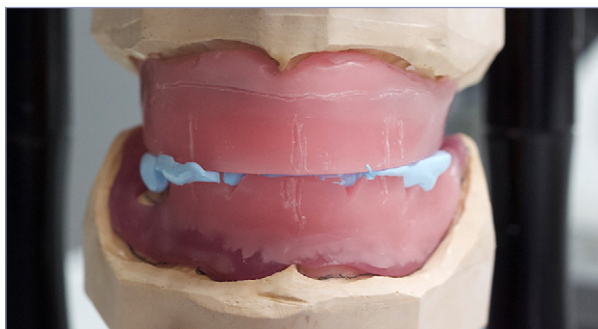appearance that offered her peace of mind with a secure grip when chewing and speaking. After detailed consultation, she decided to have a new full denture made. For this purpose, the VITAPAN EXCELL denture tooth was selected in the appropriate tooth shape to ensure a natural appearance and setup in accordance with esthetic guidelines. In the posterior area, VITAPAN LINGOFORM was used. As an initial basis for the work to be completed, anatomical situation impressions were taken with alginate in order to create custom trays in the laboratory. These were used in a second session to take mucodynamic impressions. The first impression was taken using Heavy Body, and the second, fine impression using Light Body A-silicone. Once the master model had been fabricated, this was used as a basis for fabricating bite registrations with wax rims for determining jaw relation. The spatial arrangement of the jaws in relation to one another could be transferred to the articulator using the intraorally encoded registration data. Following analysis of the model, the appropriate wax setup for the patient was started.



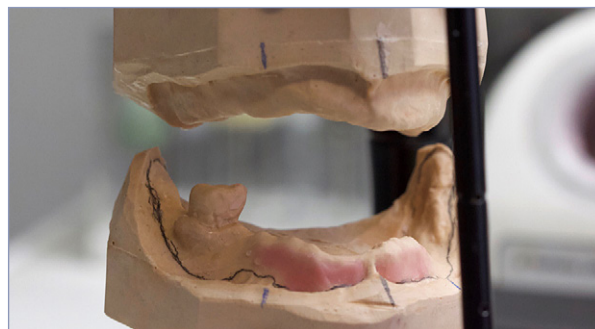The patient's insufficient dentures needed to be restored.



Two-phase mucodynamic impressions were taken of the upper and lower jaw.



The master models were articulated using jaw relation determination.

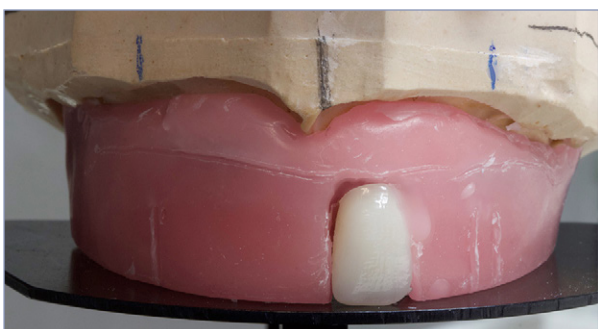


After model analysis, it was possible to begin setup.

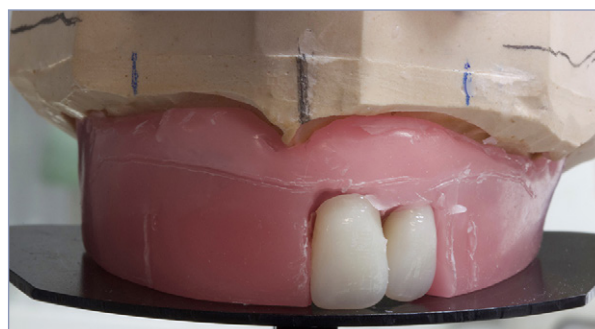Intuitive setup

Dental technicians have internalized the esthetic guidelines. In addition to their fundamental knowledge of esthetics, they spend every day looking at what works esthetically and what doesn't. A logical consequence is that they find it easier to set up with anterior teeth that comply with these esthetic rules than, for example, with a set of teeth whose axis and angle characteristics do not harmonize with each other on the dental plate. Even with these kinds of denture teeth, every user will try to find the ideal setup, although they will find it difficult to find the correct tooth position, given the fundamental discrepancies. That's why VITAPAN EXCELL was designed with tooth axes, contact surfaces, angle characteristics, cervical dimensions, gingival margins and length-width ratios that consistently meet the generally-applicable esthetic guidelines of natural dentition. As a result, setup using this anterior tooth set was intuitive and easy to complete. The wide palatal ridges additionally support optimal shaping of the papilla. For new restorations, it is important to always consider the previous

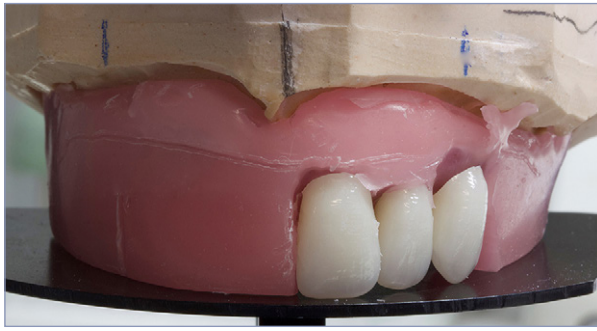
appearance of the patient's dentition. The basis is the anatomy of the oral cavity on the day treatment started, which is where I begin restoration in accordance with the parameters of esthetics, function and stability. All clinical information must be taken into consideration here to achieve optimal restoration results in the patient's mouth. Due to the position and the mesial displacement of tooth 46, space for the lower anterior setup was restricted and was implemented with overlap in order to facilitate physiological molar contact between the denture teeth. The patient was in agreement, as her natural lower anterior teeth had also overlapped and had never been evened out by orthodontic treatment. In the posterior area, efficient setup with precisely defined centricity, but with the necessary freedom for excentric movement, was ensured by VITAPAN LINGOFORM. The multifunctional occlusal surface design based on the cog wheel principle, is universally suited for all conventional tooth-to-tooth or tooth-to-two-tooth set-up concepts.



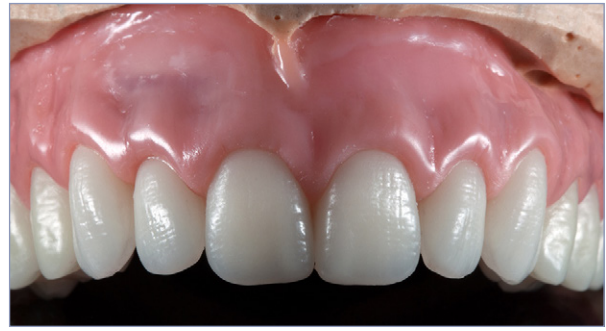Due to the morphology of VITAPAN EXCELL, setup took place automatically in accordance with esthetic guidelines.



Tooth 22 was slightly inclined in the palatal direction to facilitate an individual appearance.



It was possible to complete the anterior setup quickly through integrated esthetics.

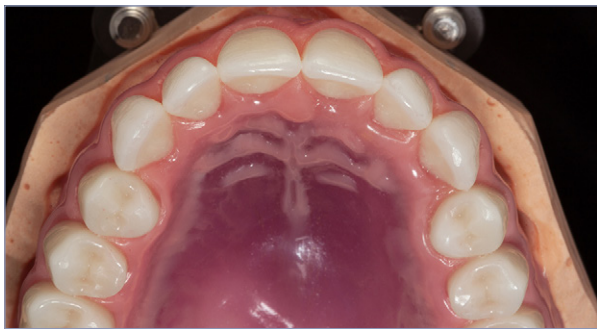

The upper denture with modeling complete and the natural play of light of VITAPAN EXCELL.

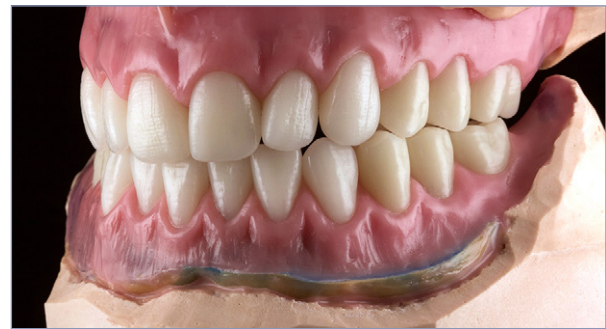Finishing and try-in

Since the gradient of the gingival garland is not defined by a stepped transition between the tooth and the cervical area, but the transition is natural, the mucogingival structure could be modeled in a patient-friendly way. The alveolar process, palatal ridges and palatal suture, as well as the incisive papilla, were also modeled in wax in order to simulate the final dentures as accurately as possible during clinical try-in. Following careful analysis, the posterior teeth were adjusted to a more distal position in order to achieve a more individual and natural appearance. The single tooth (46) was enclosed in a circular fashion by the base to provide the upper setup with greater occlusal stability and to compensate for distal movement of

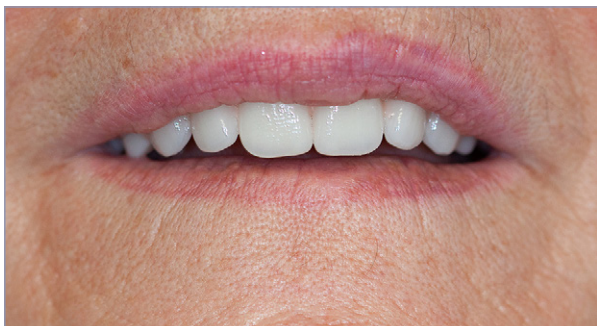the tooth. The patient responded well phonetically and functionally, and was delighted with the natural appearance of the denture teeth. Thanks to the three-dimensional anatomical structure in multiple layers, and the harmonious shade gradient from the neck to the incisal area, the VITAPAN EXCELL anterior tooth set had an incredibly lifelike appearance. Its natural morphology and nuanced surface texture facilitated a brilliant play of shade and light in the patient's mouth, even during try-in. The distinctive incisal characteristics with a white incisal margin and integrated mamelon structure created an organic shade effect, while the balanced light transmission resulted in natural light dynamics.



The palatal anatomy was also precisely simulated for try-in.



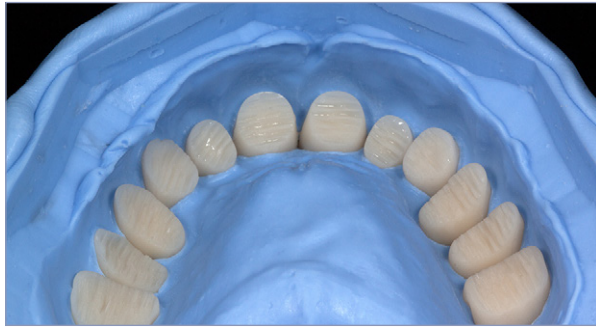The upper and lower denture with modeling complete in the articulator.



The patient was already delighted with the esthetic result during try-in.

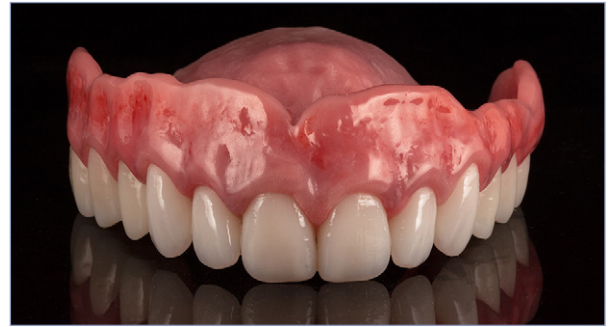Completion and finishing

A silicone key was fabricated from the wax setups; the teeth were removed, cleaned and conditioned in the base and cervical areas for acrylic fabrication. Following repositioning of the denture teeth in the silicone key and prior to pouring, the complete denture base was customized with Castdon polymer, and the vestibular labial shield and palate area customized using shades from the Denture Art system (both products from Dreve Dentamid, Unna, Germany). Following repositioning of the master model in the key and autopolymerization,

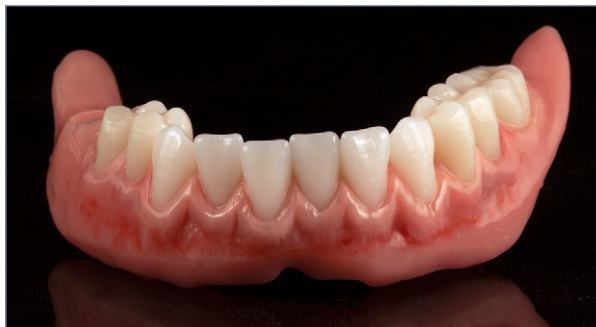

The cleaned and conditioned denture teeth repositioned in the silicone key.

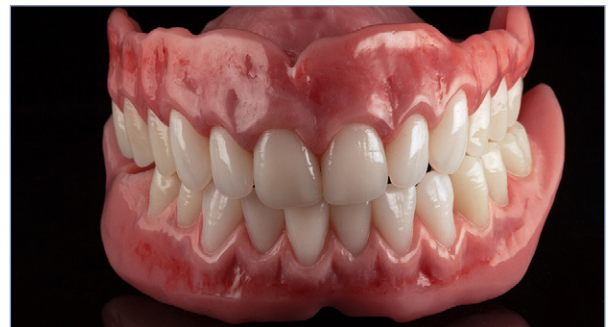both dentures were finished using a rotating instrument. Final polishing was carried out using a pumice stone, polishing paste and a polishing wheel. Depending on the age of the patient, the age of the teeth can be controlled by reducing the surface texture to a greater or lesser degree by quickly polishing. In this case, the surface texture of the teeth were consistently avoided by using a handpiece in order to maintain a more youthful appearance for the denture teeth.



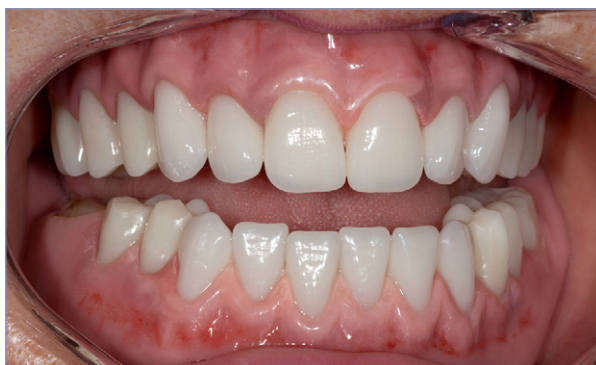The completed, finished upper denture had a completely natural appearance.



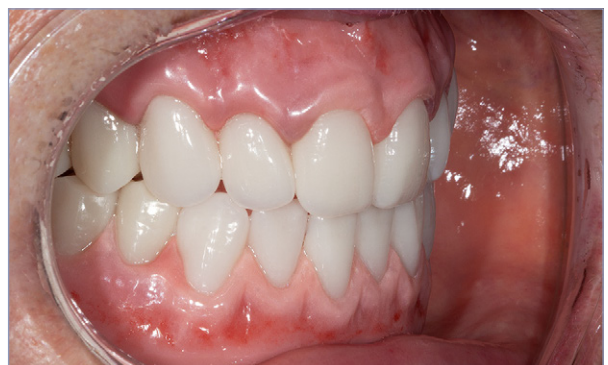The slight overlap in the lower anterior area provided an individual appearance.



The highly esthetic full denture restoration prior to insertion.



Both dentures could be integrated harmoniously in the oral cavity.

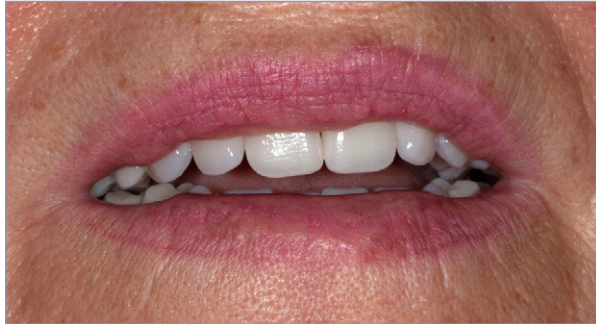

Denture teeth and mucogingival reproduction formed a natural-looking restoration.

Highly esthetic full dentures

This case shows that by using the right denture teeth in accordance with esthetic guidelines, and by working with a creative dental technician, it is possible to create full denture restorations that compare favorably with complete ceramic jaw restorations. The patient was delighted with the highly

esthetic result and the stable seating of her new dentures, and was already more confident immediately after placement. The denture teeth showed a lifelike play of light and gave the patient an age-appropriate appearance again.



The patient was completely satisfied with the highly esthetic result.

More information and case reports on:
https://www.vita-zahnfabrik.com/VITAPAN_EXCELL



VITA® and the VITA products mentioned are registered trademarks of VITA Zahnfabrik H. Rauter GmbH & Co. KG, Bad Säckingen, Germany.

We would appreciate a sample copy of any reprints.

VITA Zahnfabrik
H. Rauter GmbH & Co. KG
Spitalgasse 3
79713 Bad Säckingen
www.vita-zahnfabrik.com

VITA